

1010 Vermont Ave NW, Suite 600  
Washington, DC 20005  
(202) 638-5872  
[www.sbh4all.org](http://www.sbh4all.org)



# Hearing Hoof Beats From A Distance: Primary Care and Telehealth

Steve North  
Kelli Garber  
Stormee Williams

August 12<sup>th</sup>, 2020





## We Believe...

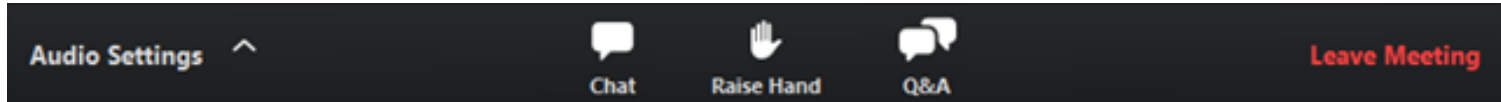
In the transformational power  
of the health and education  
intersection




**Re-Imagining School-Based Healthcare Together :**  
SUPPORTING STUDENTS NOW AND IN THE FUTURE

## REMINDERS


-  All attendees are in **listen-only mode**.
-  We want to hear your questions! To ask a question during the session, use the **“Q&A” icon** that appears on the bottom your Zoom control panel.



-  Please complete evaluation poll questions at the end of the presentation.

## WEBINAR ARCHIVE

- School-Based Health Centers in the Time of COVID-19
- Suicide Prevention, Intervention, and Postvention During COVID-19: What School-Based Staff Need to Know
- Lead the Way: Engaging Youth in Health Care
- How You(th) Are the Key to Tackling the Stigma on Mental Health



# TODAY'S PRESENTER (S)



**Steve North**

Founder and Medical Director  
Center for Rural Health  
Innovation



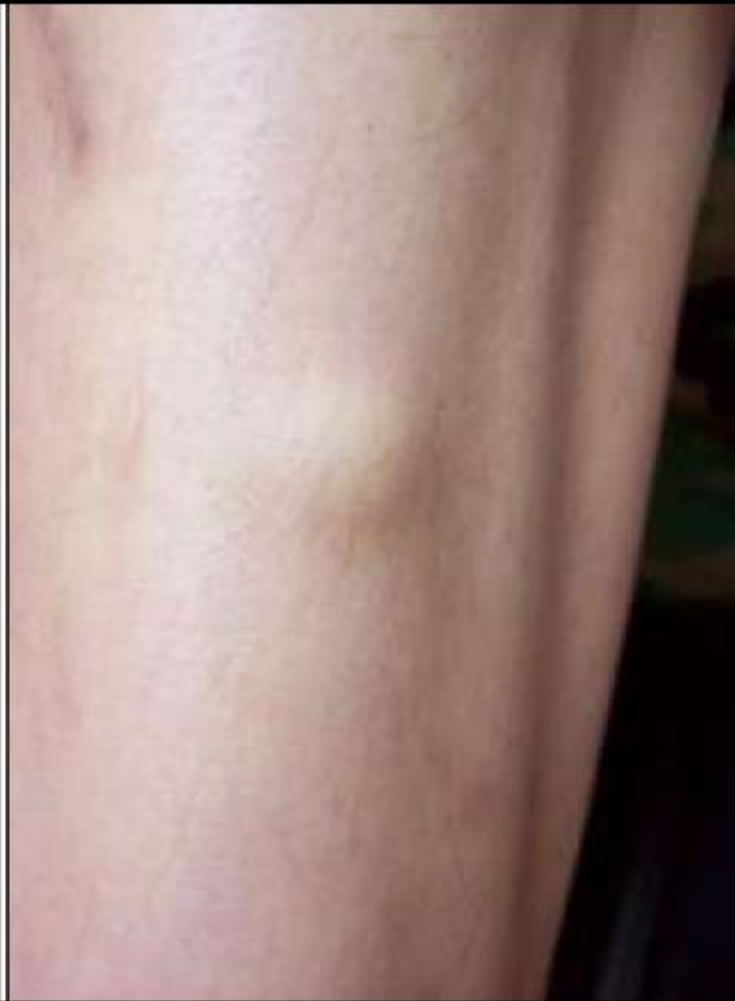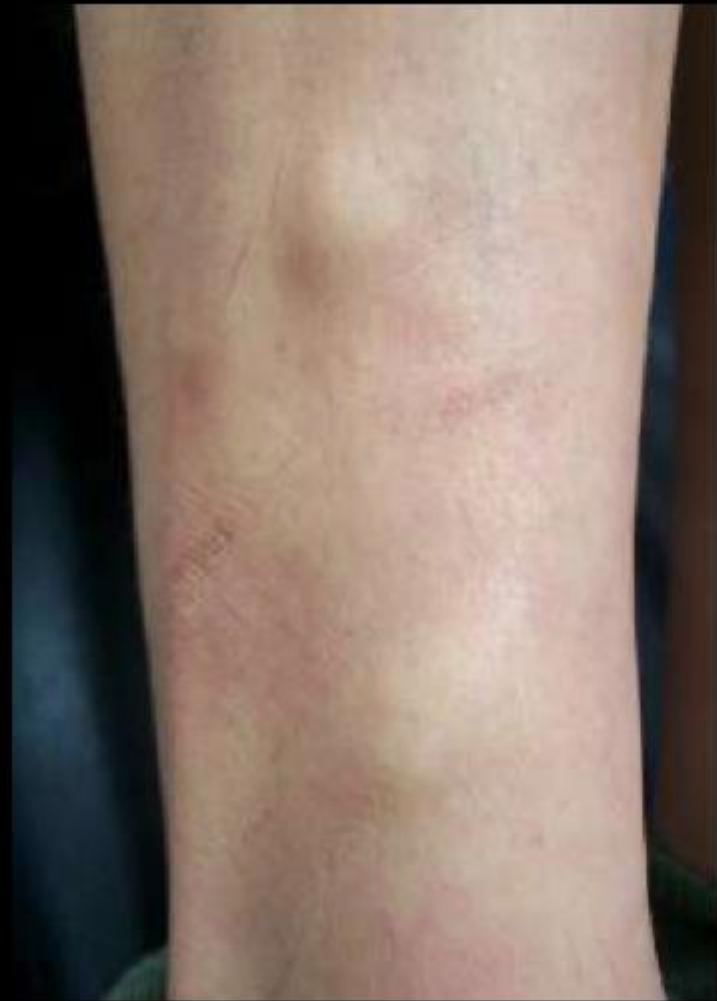**Kelli Garber**

Lead Advanced Practice Provider  
and Clinical Integration  
Specialist at The Center for  
Telehealth at The Medical  
University of South Carolina



**Stormee Williams**

Vice President and Medical  
Director at Network  
Development and Innovation  
Children's Health

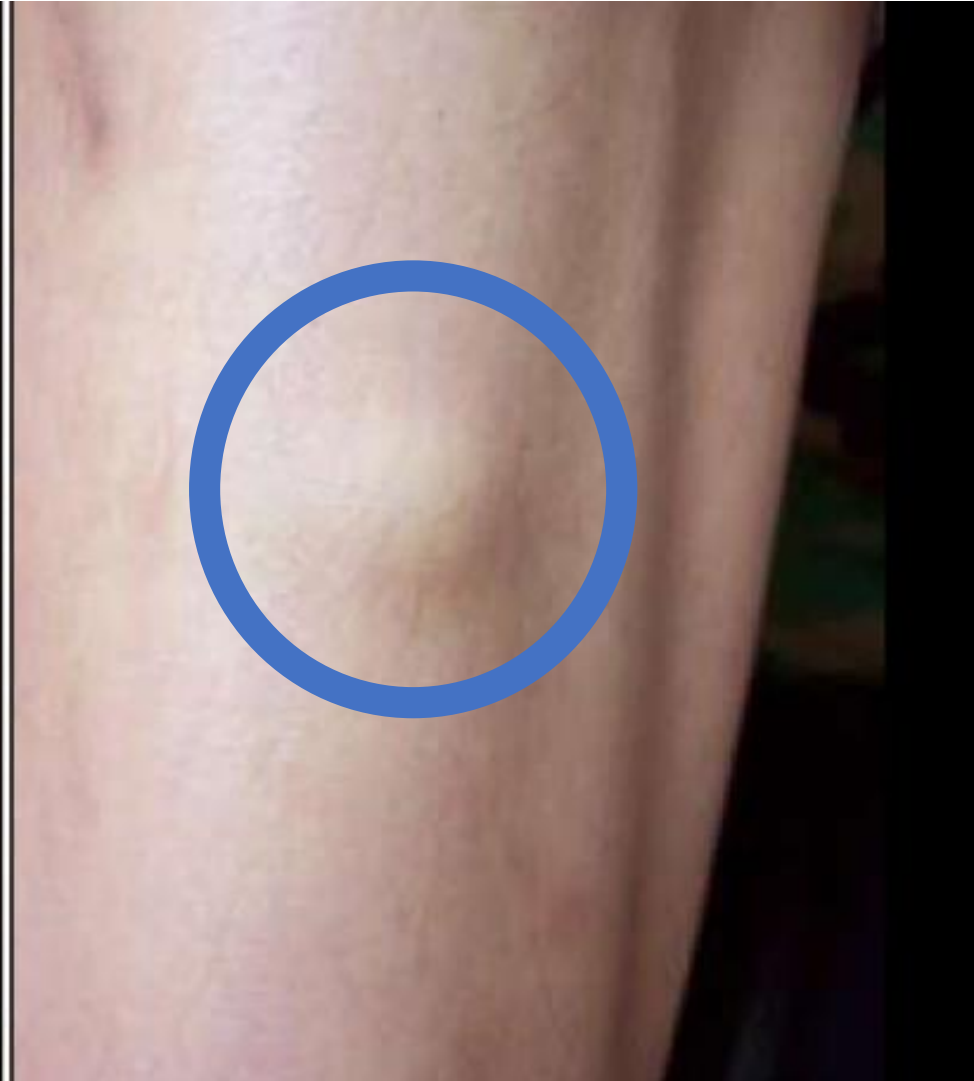
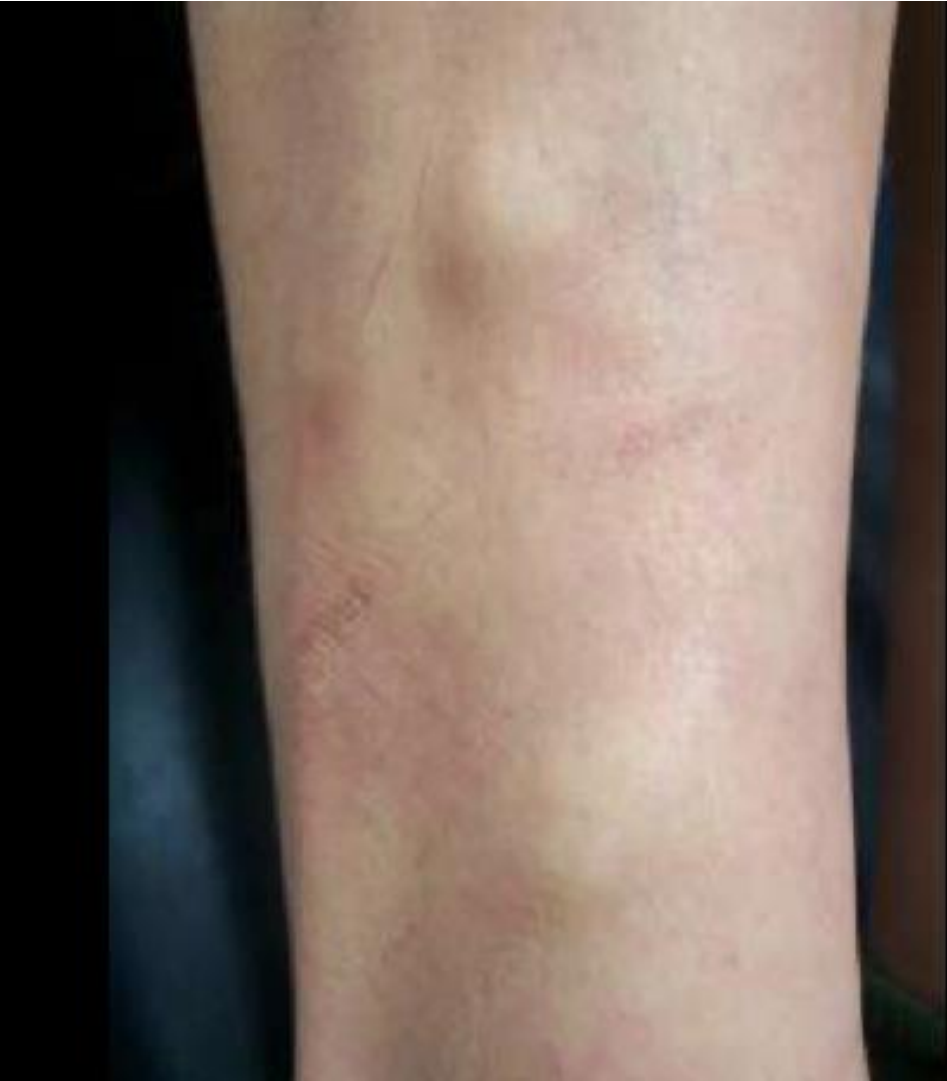
## Lumps on my legs



- 15 yo male reports the development of “lumps” on both lower legs over the past 6 months.
- Left lump is bigger and feels “full” at the end of practice.
- Playing competitive soccer with 2-4 hours of practice 6 days per week.



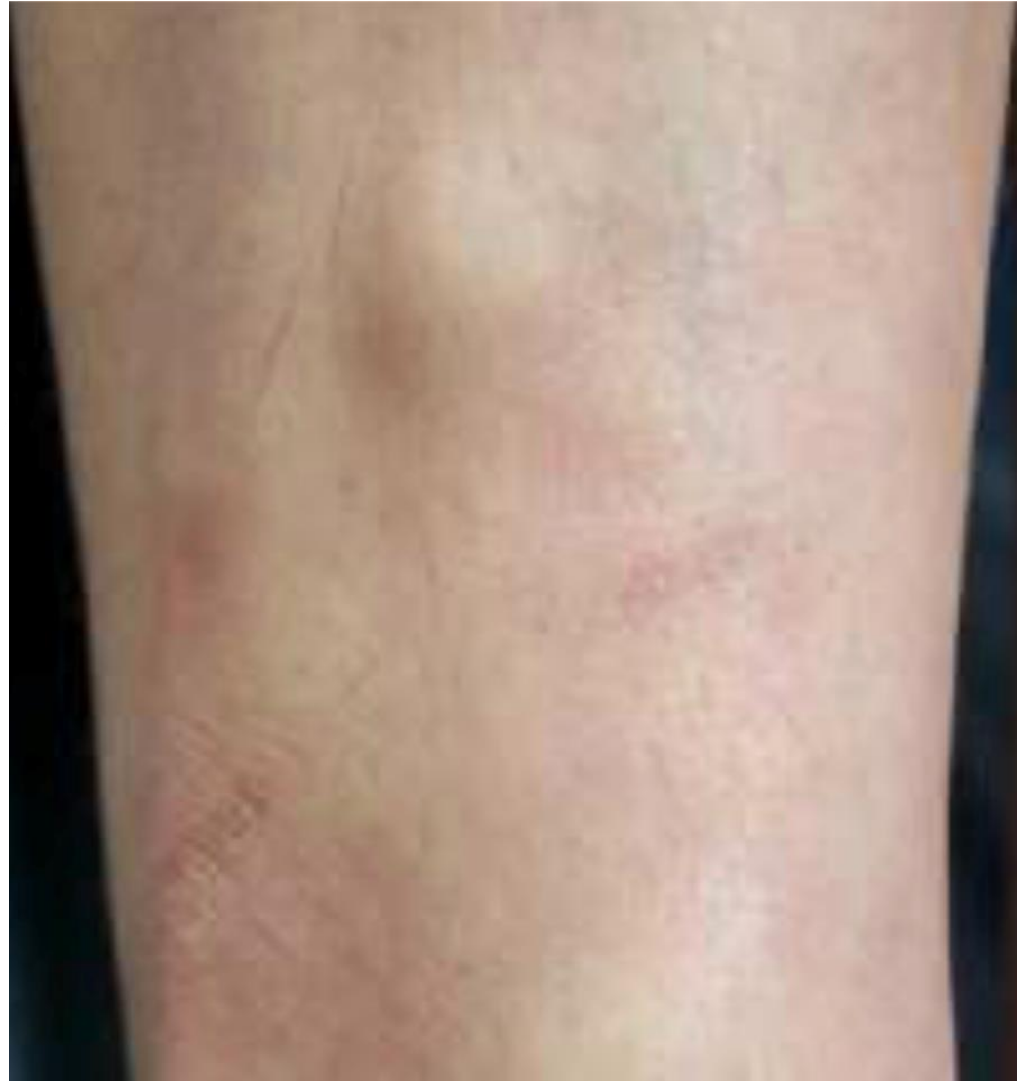

# Lumps on my legs – additional history

- Painless at rest
- Do not restrict his activity
- No family history similar masses
- SMR Stage IV
- BMI 52%ile
- Other questions?

# Physical Exam

- guided exam with patient palpating his legs
- multiple subcutaneous masses on both legs
- non-tender, non-inflamed, non-fluctuant compressible
- most prominent mass 2 cm in diameter on the left calf

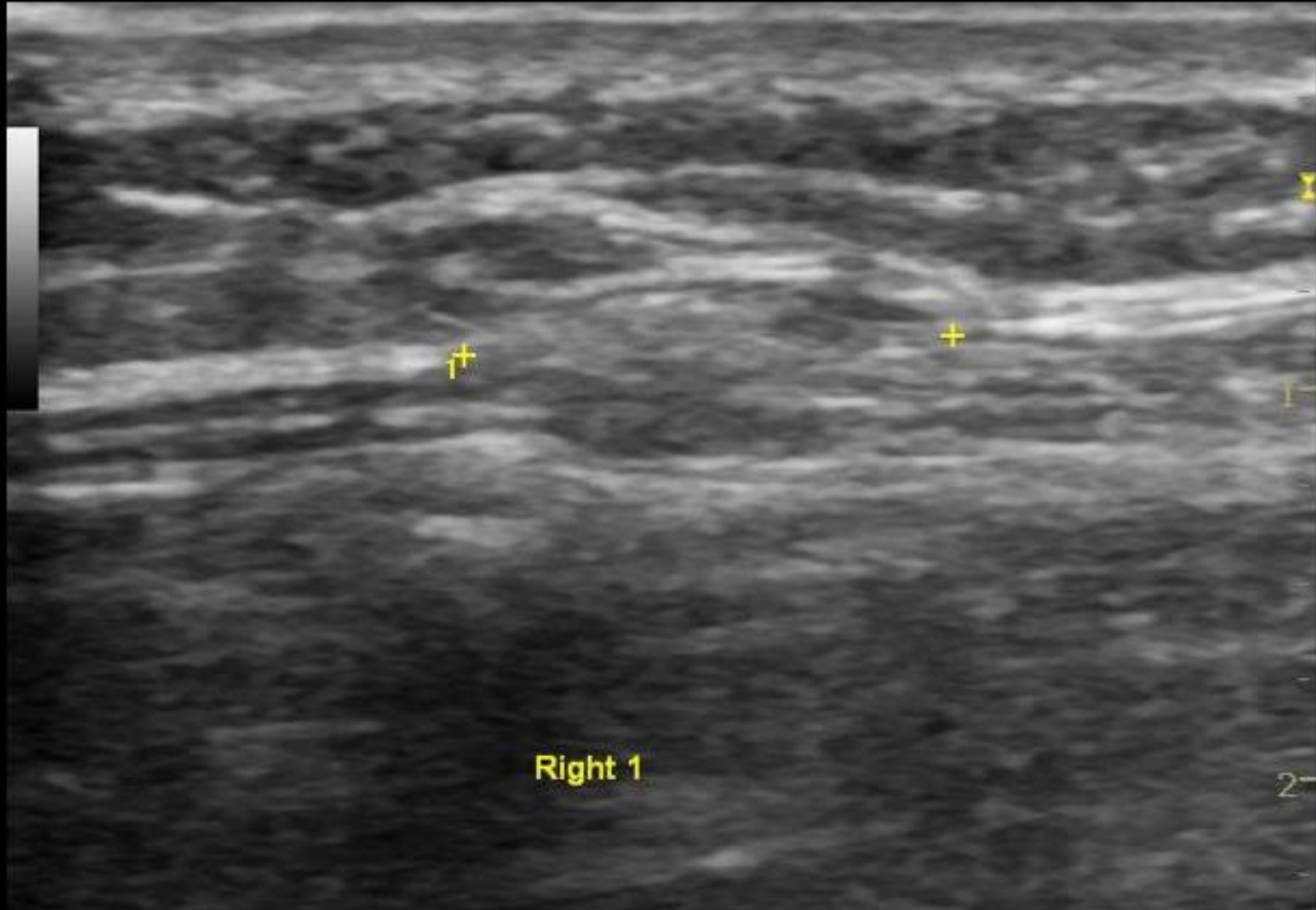


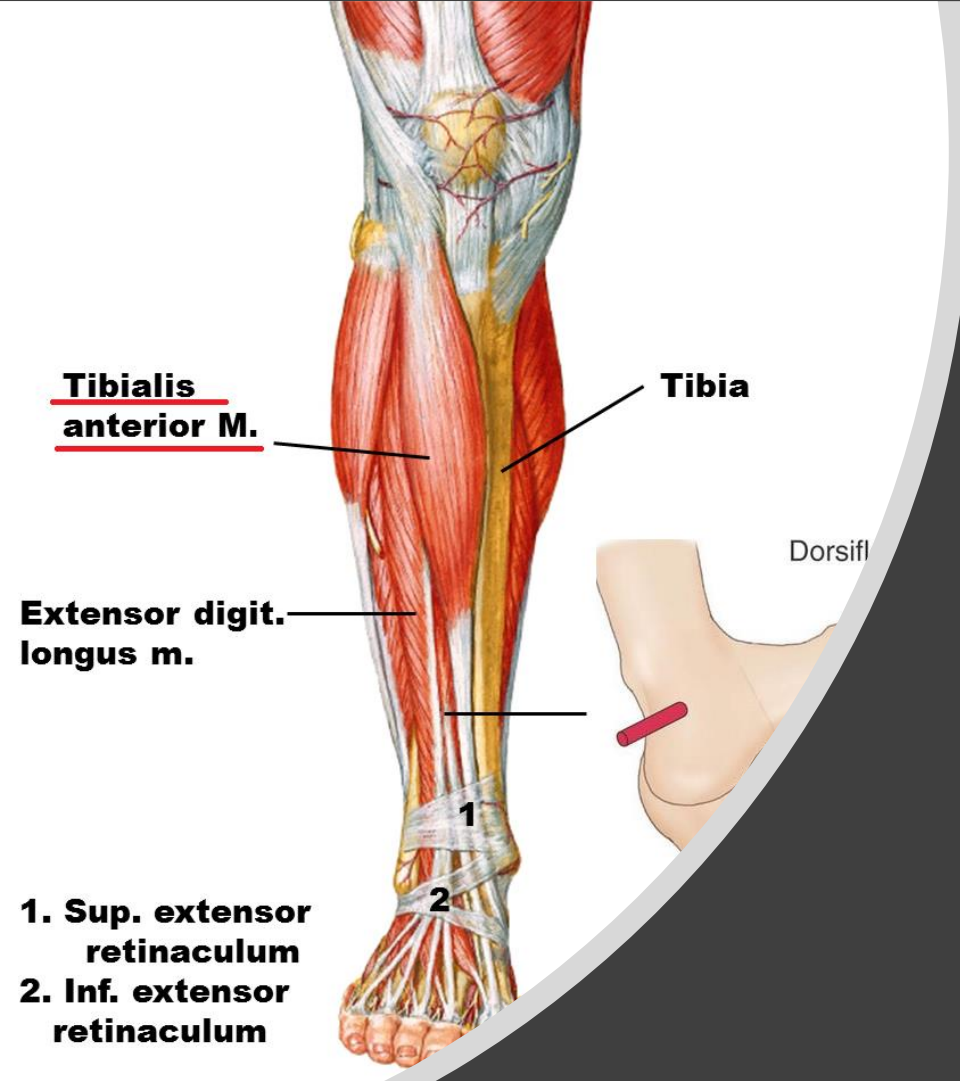
Question 2: Which of the following causes do you feel is most likely?

- A. Infectious
- B. Oncological
- C. Metabolic
- D. Musculoskeletal
- E. Vascular

Question 2: What additional studies would you order?

- A. Labs (please put ideas in the chat)
- B. X-ray
- C. Ultrasound
- D. MRI
- E. Biopsy
- F. None





# Tibialis Anterior Muscle Hernia

- Often present with a dull ache after exertion
- Most common in adolescent male athletes
- Primary: Congenital weakness in the fascia
- Secondary: Repetitive trauma (soccer)
- Can be painful and result in nerve entrapment
- Typical treatment is compression stocks
- Surgery can be performed to repair the fascia in extreme situations

# Ocular **Redness**: It's More Than Meets the Eye

Kelli Garber, MSN, APRN, PPCNP-BC  
Lead Advanced Practice Provider and Clinical Integration Specialist  
Medical University of South Carolina Center for Telehealth





# Disclosure

I have nothing to disclose.



# Case History

Johnny is an 8 year old male who presents to the school nurse with a complaint of red eyes. His mother suspects pink eye. The school nurse refers him to the school-based telehealth program for further evaluation to help determine if he must be sent home.

Upon initiating the visit, the nurse practitioner obtains additional history from the patient, the school nurse and the mother who is available by phone.

**What else do we need to know?**



# History of Present Illness

- Duration of ocular erythema: 2 months
- History: No trauma
- Associated symptoms:
  - Tearing
  - Photophobia
  - Absence of Drainage
  - Pain
  - Absence of itching
  - Mild upper respiratory symptoms (congestion/cough)
  - Vision change present
  - Absence of swelling
- Treatments
  - Loratadine
  - Cetirizine HCL
  - Olopatadine HCL .2% eye drops



# Pertinent History

## Past Medical History

- Healthy male
- Up to date on immunizations
- Seasonal allergies, usually in the spring
- NKDA
- No history of asthma or lung disease
- No history of joint problems
- No ongoing medical concerns
- Has not been seen by an ophthalmologist but has had normal vision screens at school
  - Last was this past fall



# Pertinent History

## Social History

- Lives with mother, father and 5 year old brother

## Family History

- Everyone has spring allergies
- Brother has asthma
- No other significant illnesses



# History of Present Illness: Case Summary

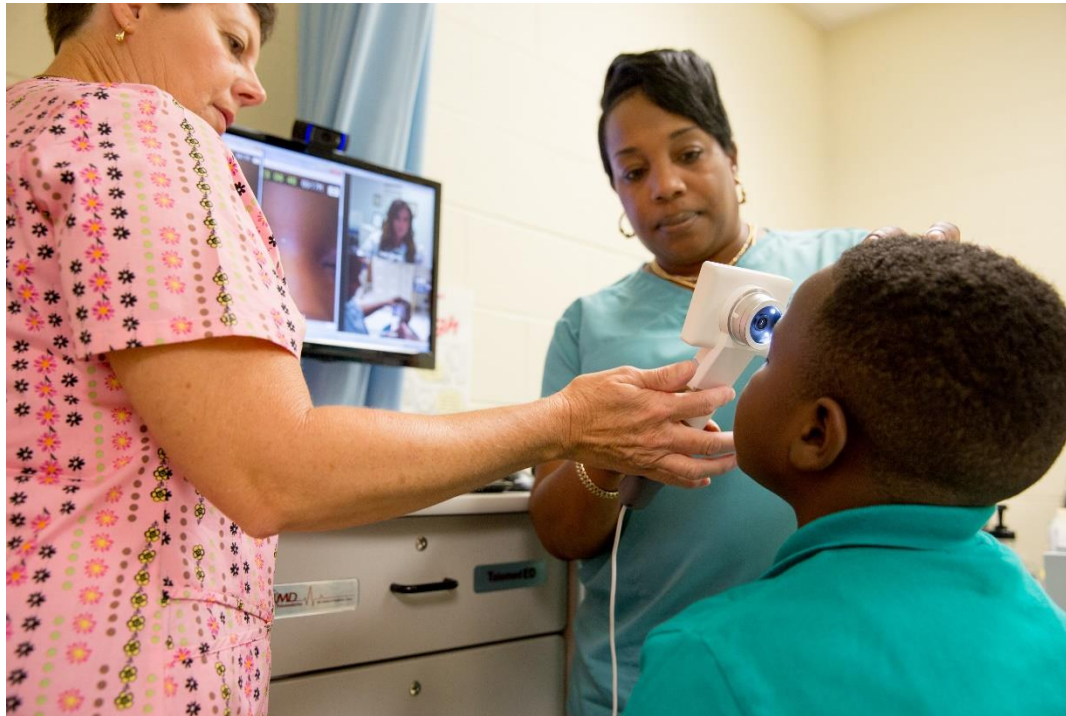Johnny is an 8 year old African American male who presents to the school nurse with a complaint of red eyes. He began with red eyes about two months ago and was seen by his primary care provider who diagnosed him with seasonal allergies and started Claritin. His eyes continued to be red and the redness worsened so the school nurse referred him to be seen again. The second provider also diagnosed allergies. He was changed to Zyrtec and an allergy eye drop (olopatadine/pataday) was added, which he has been taking for 2 weeks.

He has never had itching or discharge but his eyes do water at times. He is increasingly sensitive to light, closing his eyes if he is outside. He has also been complaining of eye pain. No fever. No sore throat. He does have mild congestion and cough. No ear pain. No abdominal complaints. No vomiting or diarrhea. No joint complaints. No recent insect or tick bites.

The teacher noted that he has been squinting more when looking at the board.

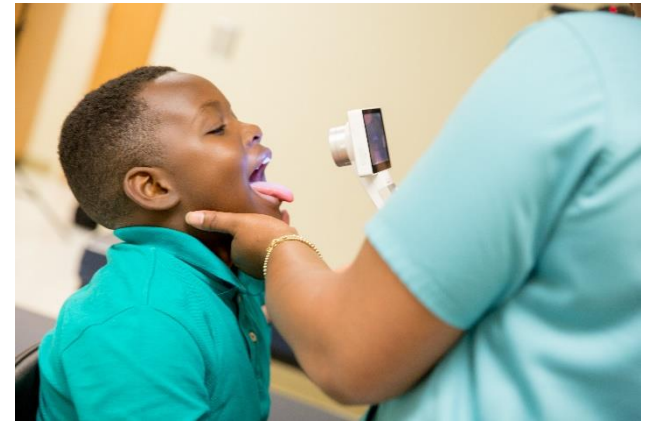


# Telehealth Physical Exam



# Virtual Visit Exam Techniques

- School-Based Telehealth Visit
  - Physical exam
  - Telemedicine peripheral devices
    - Stethoscope
    - Otoscope
    - Exam Camera
    - No ophthalmoscope





# Virtual Visit Exam Techniques

- Video Only Telehealth Visit
  - Physical Exam Without Peripherals
    - Overall disposition
    - HEENT
      - Head
      - Eyes: redness, edema, discharge, tearing, photophobia, EOMs
      - Ears-deferred
      - Nose: congestion, discharge, flaring
      - Throat: oropharynx, mucous membranes, tongue
    - Respiratory: effort, respiratory rate
    - Cardiac: deferred
    - Abdomen
    - Skin



Image Credit: Stockfresh, used with permission



# Physical Assessment

**General:** Well appearing 8 year old male. Normocephalic.

**Eyes:** Both eyes are noted to have moderate erythema of the conjunctiva. He is sensitive to light and noted to have tearing which worsens, when in the light. No thick or discolored drainage from the eyes. Vision screen reduced from 20/20 in October to 20/50 in March

**Ears:** External ear exam is normal, tympanic membranes are gray with visible landmarks and light reflex.

**Nose:** Mild nasal congestion with clear rhinorrhea. Turbinates are pale and boggy.

**Throat:** No redness, exudate or lesions. Tonsils are 2+, mucous membranes are moist.

**Neck:** FROM

**Respiratory:** Even and unlabored, RR 18. Lungs are clear to auscultation.

**Heart:** Rate and rhythm are within normal limits with a pulse of 80.

**Abdominal:** Deferred due to history and telehealth encounter

**Skin:** No rash



# What's Your Diagnosis?

- A. Allergic Conjunctivitis
- B. Bacterial Conjunctivitis
- C. Viral Conjunctivitis
- D. MIS-C (Multisystem Inflammatory Syndrome in Children)
- E. None of the Above/ Needs further evaluation



# Uveitis/Iritis

**Uveitis** is a form of eye inflammation. It affects the middle layer of tissue in the eye wall (uvea).

**Iritis** is the inflammation of the colored part of the eye (iris). This is also referred to as **anterior uveitis**.

## Red Flags

- Pain
- Tearing
- Photophobia
- Decreased vision
- Blurry vision
- Dark spots/floaters

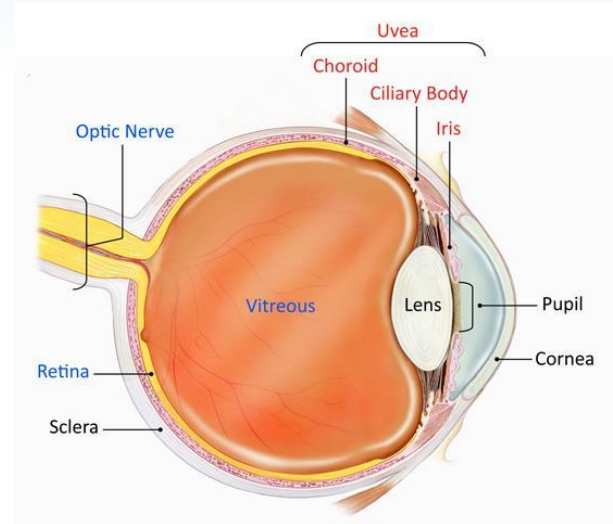


Image: National Eye Institute,  
<https://www.nei.nih.gov/learn-about-eye-health/eye-conditions-and-diseases/uveitis>



# Uveitis/Iritis

## Causes

- Infection
- Injury
- Autoimmune disease

## Possible Disease Associations

- AIDS
- Ankylosing spondylitis
- Herpes zoster infection
- Kawasaki disease
- Multiple Sclerosis
- Psoriasis
- Rheumatoid arthritis
- Sarcoidosis
- Tuberculosis
- Ulcerative Colitis



# Final Diagnosis: Sarcoidosis

- Chronic inflammatory condition involving the growth of small collections of white blood cells in various parts of the body including the lungs, lymph nodes, joints, eyes and skin (granulomas).
- Incidence is estimated to be 10-20 per 100,000
- Rare in children, more common in adults (20-60 years of age)
- More common in African Americans than Caucasians
- Children of African descent may have more severe and extensive disease compared to those of Caucasian or Asian descent
- Cause is unclear but may involve immune response to chemicals, infectious agents, or the body's own proteins
- Increased risk if family history but no gene has been identified yet



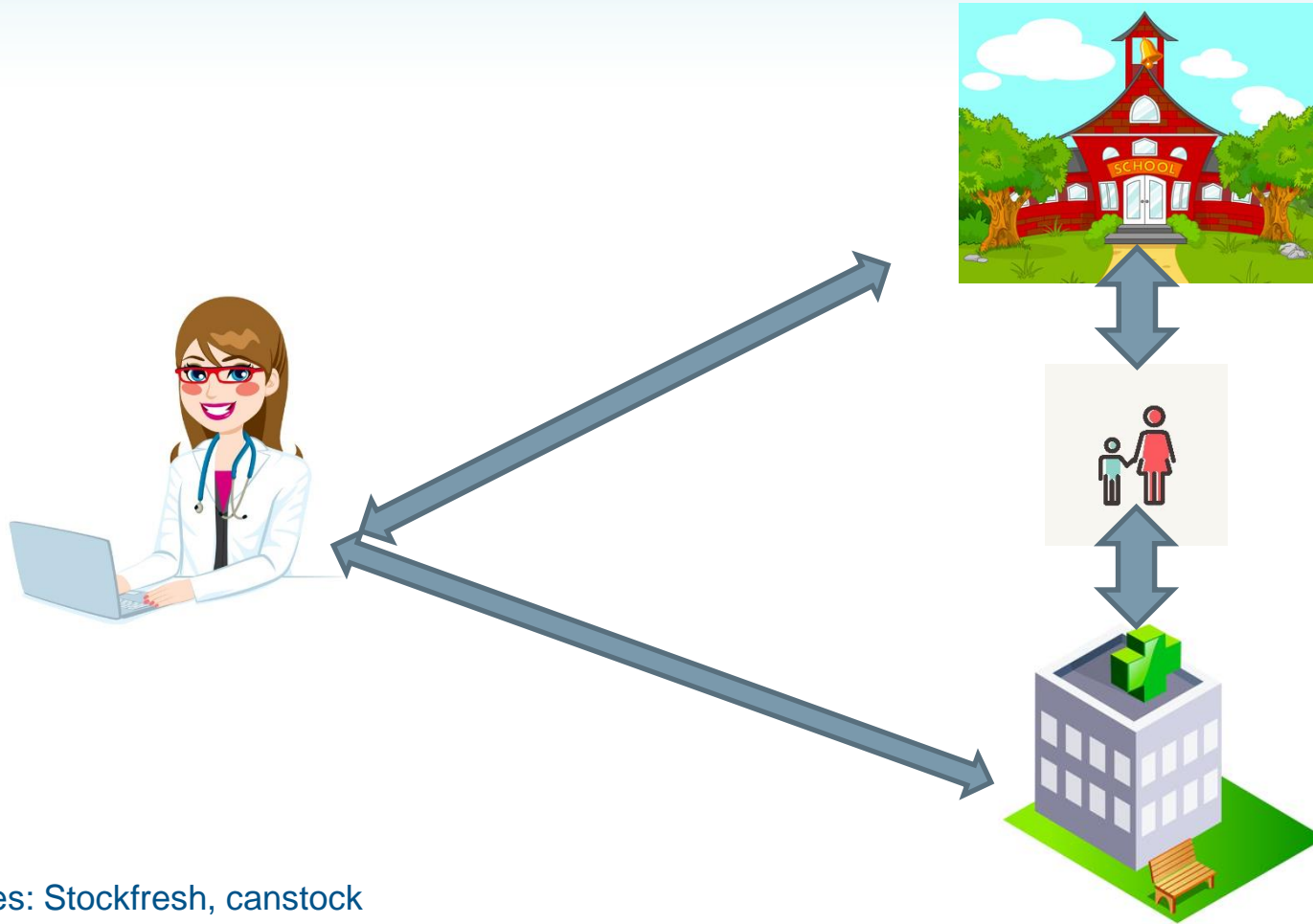
# Final Diagnosis: Sarcoidosis

## Symptoms in Children

- Skin rash
  - Granulomas
  - Erythema nodosum
  - Sores on the nose, cheeks or ears
- Arthritis
- Uveitis
- Lung involvement
  - Persistent dry cough
  - Shortness of breath
  - Wheezing
  - Chest pain
  - Abnormal chest X-rays
    - Bilateral hilar adenopathy
    - Pulmonary reticular opacities



# Telehealth: Connecting Kids to Care



Images: Stockfresh, canstock





# Resources

## Old Dominion University Center for Telehealth Innovation and Education (CTIER)

### Telehealth Exam Video Links

Telehealth Etiquette <https://www.youtube.com/watch?v=sYsrFW6BFBs>

Cardiopulmonary <https://www.youtube.com/watch?v=e8OhK7V9Cp4>

Skin <https://www.youtube.com/watch?v=TFxZ9qssZT0>

Abdominal exam <https://www.youtube.com/watch?v=eMNI4MEK328>

ENT [https://www.youtube.com/watch?v=W\\_d9L89C4m0](https://www.youtube.com/watch?v=W_d9L89C4m0)

Musculoskeletal exam <https://www.youtube.com/watch?v=VKti8ZP4WTE>



# Resources

## **National Centers for Telehealth Excellence**

The Medical University of South Carolina (MUSC)

<http://www.muschealth.org/telehealth/index.html>

University of Mississippi (UMMC)

[https://www.umc.edu/Healthcare/Telehealth/Telehealth\\_Home.html](https://www.umc.edu/Healthcare/Telehealth/Telehealth_Home.html)

## **American Academy of Pediatrics Section on Telehealth Care**

<https://www.aap.org/en-us/professional-resources/practice-transformation/managing-patients/telehealth-care/Pages/default.aspx>

## **American Telemedicine Association**

<http://www.americantelemed.org/home>



# Resources

## **Telehealth Resource Centers**

<https://www.hrsa.gov/library/telehealth-resource-centers>

## **Center for Connected Health Policy (CCHP)**

<http://www.cchpca.org/state-laws-and-reimbursement-policies>

## **Telehealth Technology Assessment Resource Center**

<https://www.telehealthresourcecenter.org/ttac/?Center=TTAC>

## **Regional Telehealth Resource Centers**

<https://www.telehealthresourcecenter.org/who-your-trc>



## References

Mayo Clinic. (2020). *Uveitis*. <https://www.mayoclinic.org/diseases-conditions/uveitis/symptoms-causes/syc-20378734>

National Eye Institute. (2020). *Uveitis*. <https://www.nei.nih.gov/learn-about-eye-health/eye-conditions-and-diseases/uveitis>

Riley Children's Health. (2020). Sarcoidosis. <https://www.rileychildrens.org/health-info/sarcoidosis#:~:text=The%20most%20common%20symptoms%20of,Difficulty%20moving%20the%20joints>

King, T. (2020). Clinical manifestations and diagnosis of pulmonary sarcoidosis. *Up to Date*. [https://www.uptodate.com/contents/clinical-manifestations-and-diagnosis-of-pulmonary-sarcoidosis?search=sarcoidosis%20children&source=search\\_result&selectedTitle=1~150&usage\\_type=default&display\\_rank=1](https://www.uptodate.com/contents/clinical-manifestations-and-diagnosis-of-pulmonary-sarcoidosis?search=sarcoidosis%20children&source=search_result&selectedTitle=1~150&usage_type=default&display_rank=1)



# Questions?

**Kelli Garber MSN, APRN, PPCNP-BC**  
Lead Advanced Practice Provider and Clinical  
Integration Specialist  
Center for Telehealth  
Medical University of South Carolina  
Phone: 843.792.8709  
e-mail: [garberk@musc.edu](mailto:garberk@musc.edu)





## **Case Studies from the Virtual Field**

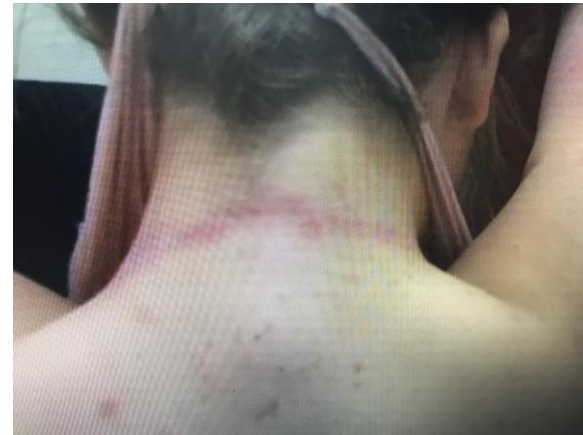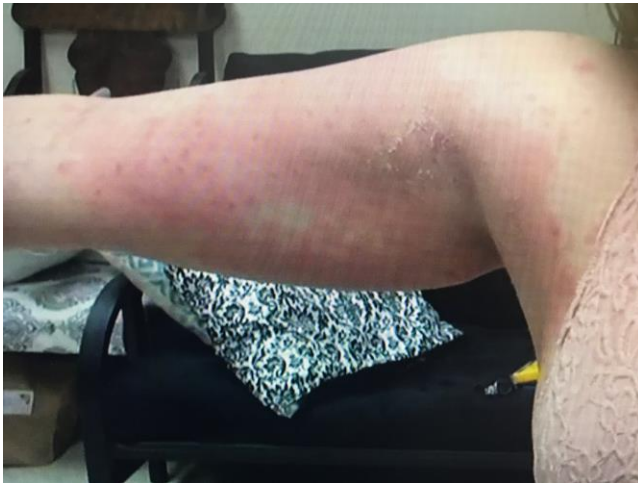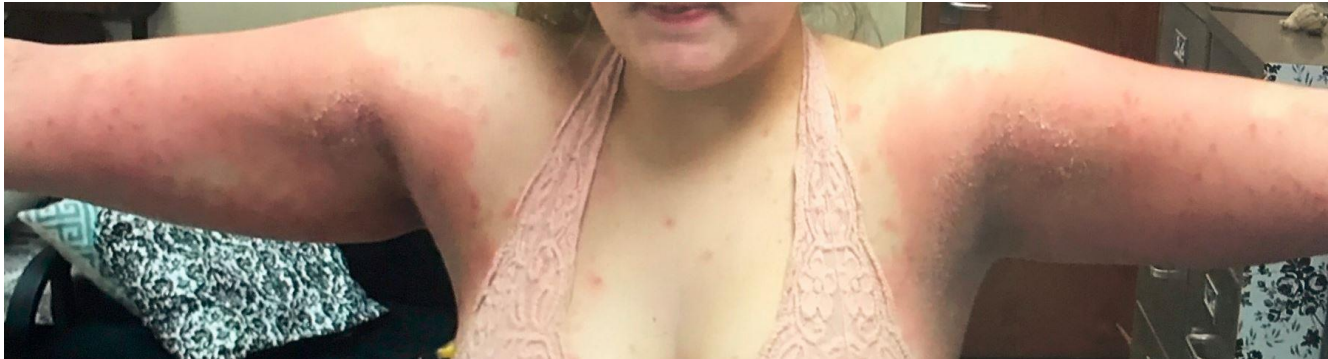Stormee Williams, MD  
Children's Health  
Dallas, TX

# Case: Rash

---

- 16-year-old girl with itchy rash for 1 week
- Started in right axilla
- Treated with OTC ringworm cream and antibacterial ointment
- Got worse => had doctor-friend call in oral steroids!!
- Got worse and spread to entire upper body
- May or may not have had fever last week
- Some sore throat from allergies; no other symptoms. Feels fine now.

# Rash





# POLL: What is your diagnosis?

---

- A. Contact dermatitis
- B. Id Reaction
- C. Tinea Corporis – worsened by steroids
- D. Viral exanthem
- E. Scarlatina

# CLUE

---

- Sister and mom are present during the visit
- School nurse tells me that mom wants to do a telehealth visit for sister also for something different
- Sister has sore throat that started 2 days ago and is getting worse
- STREP 'EM BOTH!

**Dx: Scarlatina**

# Scarlatina

---

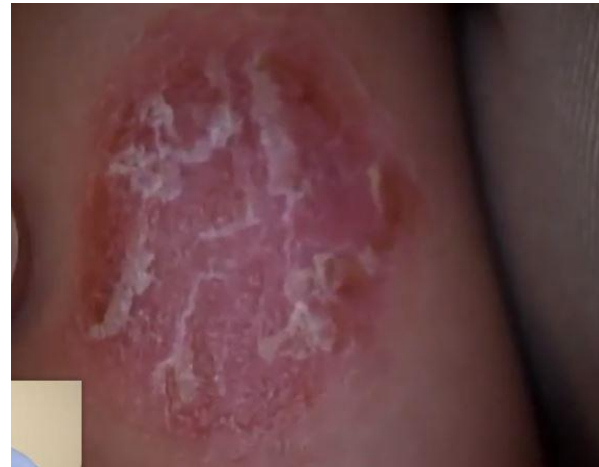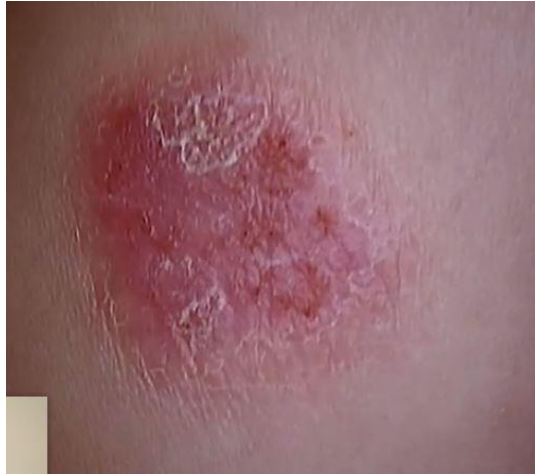- Also known as Scarlet Fever
- Due to infection by *Streptococcus pyogenese*, delayed-type skin reaction
- Diffuse erythematous rash that generally occurs with streptococcal pharyngitis
- Sandpaper rash that blanches to the touch
- Usually starts in the groin or armpits and spreads to cover the trunk and extremities
- Usually worse at skin folds and pressure points aka Pastia's Lines
- Rash tends to desquamate (peel)
- Treatment: Oral Antibiotics to prevent spread of disease and the complications of Strep infection (PCN)
- Recheck in 4 days revealed an improvement of rash

# Case 2: The Ringworm that is Spreading

---

- 16 year old male with itchy rash on right leg for 1 month
- Treated with OTC ringworm cream for about 2 weeks without improvement
- Teacher noticed that he seems to be getting more lesions and sent him to the nurse for a doctor's note saying that he wasn't contagious
- Previously healthy
- Does have a history of mild seasonal allergies
- Says his "spots" itch but not too bad

# Case 1: The Ringworm is Spreading



# Case: Keys to Diagnosis

---

- Not improving with consistent anti-fungal use
- Present for 1 month
- Healthy male, no signs of systemic disease
- Dry skin
- DDX: atopic dermatitis, contact dermatitis, tinea corporis, psoriasis
  
- And the Dx is...

# Nummular Eczema

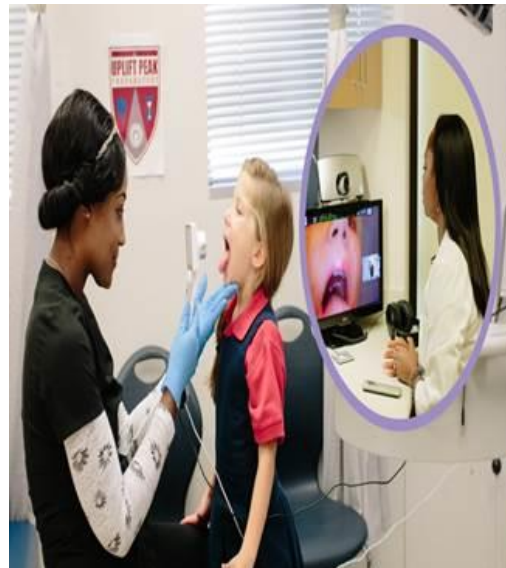# Nummular Eczema

---

- Non-contagious, chronic inflammatory skin condition
- Multiple coin-shaped, eczematous lesions usually on the extremities and lower trunk
- Similar to other forms of eczema; different appearance and distribution
- Symptoms may wax and wane with treatment and changes in environment
- RX: Reducing skin dryness and exposure to irritants
  - Mild, non-scented soaps and moisturizers twice daily
- RX: Topical Steroids
  - Moderate to High Potency Steroid creams or ointments

# Reminders

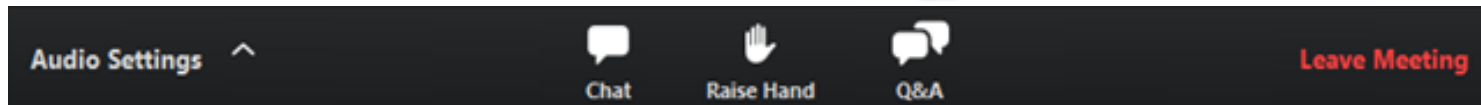
- Benefits of school-based health and telemedicine
  - You can always recheck
  - You don't have to have all of the answers
  - Use your resources – the pcp, other treating providers, etc





# QUESTIONS?

Please enter your questions into the “**Q&A**” box of the Zoom control window.





SCHOOL-BASED  
HEALTH ALLIANCE  
Redefining Health for Kids and Teens

# THANK YOU!

Additional Questions? Contact us at:

[info@sbh4all.org](mailto:info@sbh4all.org)

